Bulgarian Journal of Agricultural Science, 32 (No 1) 2026, 193–200

Bacteriological and pathological study of liver abscesses in goat carcasses in slaughterhouses

Afshin Zahedi[1*], Mohammadreza Poorghasemi[2], Masoud Shirali[3], Forogh Mohammadi[4] and Maryam Karimi-Dehkordi[5]

[1] *Department of Veterinary Pathology, Faculty of Veterinary Medicine, Islamic Azad University, Rasht Branch, Rasht, Iran*
[2] *Department of Animal Science, Faculty of Agriculture, Islamic Azad University, Rasht Branch, Rasht, Iran*
[3] *Agri-Food and Biosciences Institute, Hillsborough BT26 6DR, United Kingdom*
[4] *Department of Veterinary, Agriculture Faculty, Kermanshah Branch, Islamic Azad University, Kermanshah, Iran*
[5] *Department of Clinical Sciences, Faculty of Veterinary Medicine, Shahrekord Branch, Islamic Azad University, Shahrekord, Iran*
[*]*Corresponding author:* Zahedi@iaurasht.ac.ir; afshinzahedi19@yahoo.com

Abstract

Zahedi, A., Poorghasemi, M., Shirali, M., Mohammadi, F. & Karimi-Dehkordi, M. (2026). Bacteriological and pathological study of liver abscesses in goat carcasses in slaughterhouses. *Bulg. J. Agric. Sci., 32*(1), 193–200

The present research was conducted to determine the incidence of liver abscesses, bacterial causes, and histopathological structure in goats slaughtered in the slaughterhouse. A total of 1187 goats, including 673 male goats and 514 female goats were subjected to routine post-slaughter inspections. If an abscess was observed in the liver examination, the anatomical position of the abscess was recorded by noting the lobe and the surface. Each abscess was separated along with a part of the surrounding healthy tissue, and was sent immediately to the bacteriology and pathology laboratories for processing. There was no significant relationship between the occurrence of abscesses and the sex of goats, or between abscesses and different liver surfaces. From aerobic and anaerobic cultures of abscesses, *Corynebacterium pseudotuberculosis* was isolated from two cases, *Arcanobacterium pyogenes* from two cases, *Fusobacterium necrophorum* and *Escherichia coli* together from two cases, and *Pseudomonas spp* and *Streptococcus spp* from one case each. The results of this study showed that *Corynebacterium pseudotuberculosis*, the cause of *caseous lymphadenitis*, is an important bacterial agent in causing liver abscesses in goats slaughtered in slaughterhouses, although other less specific bacterial pathogens also cause abscesses.

Keywords: Goat; liver abscesses; *pseudotuberculosis*; *streptococcosis*

Introduction

The functional importance of the liver is well-known, and the liver is considered essential in terms of its position in life (Morales et al., 2017). Liver lesions are an important part of slaughterhouse inspections, and hepatoscopy, which means observing the liver in slaughtered animals, was first practiced in the ancient Babylonian civilization and later in Rome (Mahmood et al., 2015).

The liver plays a central role in processing carbohydrates, lipids, amino acids, and dietary vitamins, in the synthesis and recycling of plasma proteins, and in the detoxification and disposal of endogenous waste materials and xenobiotic compounds through bile (Gascoigne et al., 2020). The liver also functions as an important organ of the innate immune system, participating in a complex system of defense against foreign macromolecules (Domenis et al., 2018). Liver pathological disorders can have many causes such as toxic, parasitic, viral,

bacterial, and fungal, and can cause heavy economic losses directly by the rejection of damaged livers in the slaughterhouse or indirectly by affecting livestock growth, health, products and reproduction. Liver disorders have many consequences, which reflect the dependence of other organs on the metabolic function of the liver (Mathewos and Fesseha, 2022).

In ruminants, especially fattening cattle, liver abscesses are observed more often than in any other class of livestock. Liver abscesses cause huge economic losses by reducing feed intake, reducing weight gain by 3 to 8%, losses due to clinical syndromes, and condemnation of infected livers in the slaughterhouse (Torky et al., 2023).

Considering the large population of goats and the lack of comprehensive and complete statistical information about liver abscesses in goats, as well as adopting appropriate strategies to prevent the occurrence of large economic losses, caused by this condition in the goat population, the present study has been performed to obtain appropriate information, including pathology and identification of causes of bacterial liver abscesses in goats.

Materials and Methods

The present study was carried out from January to March, 2022, in an industrial slaughterhouse located in the north of Iran, in Rasht city. 1187 slaughtered goats were subjected to full routine post-slaughter inspections for the presence of liver abscesses. If an abscess was observed in the liver examination, the anatomical position of the abscess was recorded by noting the lobe, and the surface involved. Sampling included each abscess along with a part of the adjacent healthy tissue. Samples were separated from the remaining liver and were sent promptly to the bacteriology and pathology laboratories for further processing.

Laboratory procedures were accomplished after washing exterior surface of the abscesses with water, and then disinfecting the surface with alcohol. The wall of each abscess was seared with a hot spatula, and then that area was cut with a sterile scalpel blade. Samples were taken from the depth and sides of the opened abscess with a sterile needle, and were placed on culture media. Blood agar and MacConkey agar were used for primary culture. Two blood agar media and one thioglycollate medium were used for culturing each abscess. One blood agar plate was incubated under anaerobic conditions for 72 hours, while the other blood agar plate and the MaConkey agar plates were incubated under aerobic conditions for 24 hours, all plates at a temperature of 37 degrees Celsius (37°C).

A chemical reaction catalyst was used to provide anaerobic conditions in the anaerobic jar.

After the growth of the bacteria, the appearance characteristics of the colonies (shape, color, and smell of the colonies and the presence of hemolysis) were recorded, and in case of growth of several types of colonies, linear culture was performed for purification. Then the primary tests were performed in the form of gram staining and catalase, oxidase, and potassium tests. In order to isolate *Arcanobacter* on blood agar medium, by adding 5% blood after 24 hours of aerobic incubation, small, gray-white and convex colonies with a clear area, beta hemolysis was observed. Then, for confirmation, branched gram-positive bacilli were identified by gram staining. Eosin-methylene blue (EMB) agar medium was used for the detection of *E. coli*. Also, blood agar culture medium was used for the growth of *Corynebacterium*, in which small colonies with opaque appearance were created. To confirm the diagnosis of Corynebacterium, gram and bluedomethylene staining were used. For streptococci, beta hemolysis was observed on blood agar medium.

SIM, TSI, nitrate, gelatin, urea, and Simon citrate differential media were used for the final identification of bacteria that was grown. After conducting specific tests, the final stage of bacteria identification was performed using special tables. Immediately after taking the necessary samples for bacteriological tests from the abscesses and completely draining the purulent contents of the abscess, a part of the wall of the abscess capsule and the surrounding tissues were separated, prepared in dimensions of 1x1x0.5 cm^3, and were transferred to 10 % neutral buffered formalin solution for fixation. The fixative solution was changed twice during the first 24 hours, to assure the best fixation possible. After ensuring the complete fixation, the tissue samples, including a part of the abscess wall and the adjacent liver parenchyma tissue were collected, and the samples were processed by an autotechnicon device and molded in paraffin blocks.

Then, using a Leica model microtome, 5-micron-thick sections were taken from tissue samples molded in paraffin blocks and were stained by the H&E method (Bancroft and Stevens, 1982). Finally, the stained tissue sections were examined and studied using a Nickon 100 light microscope.

Statistical analysis

SPSS version 15 software and Chi-square statistical test were used to investigate the relationship between the presence of abscess and the sex of the goat, lobe, and the affected surfaces of the liver.

Results

During the inspections, a total of 6 carcasses (0.5%) were recorded as having liver abscesses from the carcasses of 1187 goats (including 673 male and 514 female goats).

Relationship between sex and relative frequency of liver abscesses

Out of six recorded cases of liver abscess (three cases (0.45%) in female goats and three cases (0.58%) in male goats) were diagnosed. Based on statistical studies using the chi-square test, no significant difference was observed between the occurrence of liver abscesses and the sex of goats ($p > 0.05$).

The relationship between liver lobes and the distribution of abscesses

Abscesses were observed in the right lobe of the liver in three cases (0.50%), in the left lobe in one case (16.5%), and in two cases (33.3%) in the right, left and quadrangular lobes of the liver (Figure 1 and Diagram 1). According to statistical studies using the chi-square test, no significant difference was observed in the number and distribution of liver abscesses in different liver lobes of goats ($p > 0.05$).

The relationship between the distribution of abscesses and surfaces of the liver

Abscesses were present in three cases (0.50%), at the diaphragmatic surface, in two cases (33.33%), at the visceral surface, and in one case (16.5%), at both surfaces (diaphragmatic and visceral). Based on statistical studies using the chi-square test, no significant difference was observed between the distribution of abscesses and different surfaces of goat liver ($p > 0.05$).

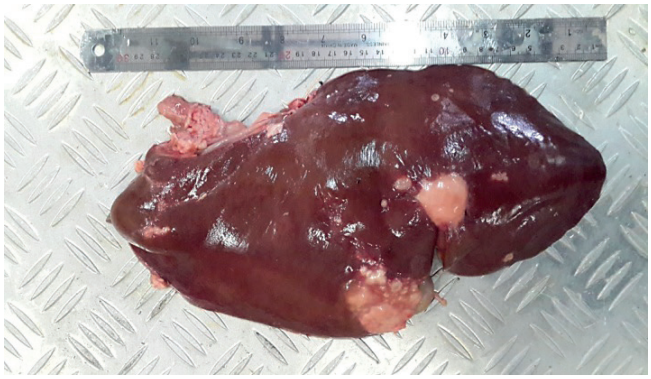

Fig. 1. Goat liver. Liver abscesses are observed in the diaphragmatic surface of the liver
Source: Authors' own elaboration

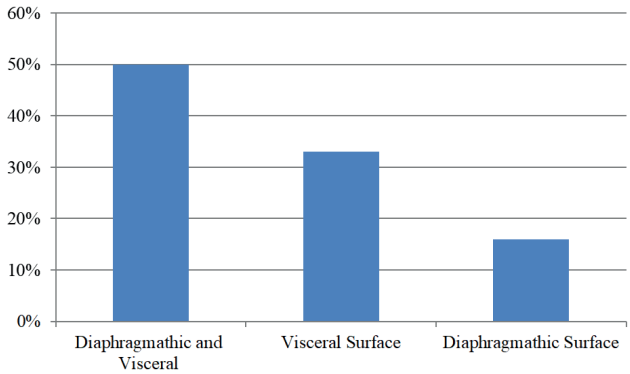

Diagram 1. The relationship between the distribution of abscesses and different surfaces of the liver. The distribution pattern of liver abscesses in different levels of the liver is shown
Source: Authors' own elaboration

Bacterial culture results

Following the bacterial culture of six liver abscesses, twelve bacteria from six different genders were isolated. Two abscesses yielded only one pathogen each, multiple pathogenic bacteria (two or three) were isolated from the other four abscesses (Table 1, Diagram 2, Figures 2 to 5).

- *Corynebacterium pseudotuberculosis* (33.33%)

Corynebacterium pseudotuberculosis was isolated as the only bacterial species from one abscess (16.6%).

Corynebacterium pseudotuberculosis along with *Pseudomonas spp* was isolated from one abscess (16.6%).

- *Arcanobacterium pyogenes* (33.33%)

Arcanobacterium pyogenes was isolated as the only bacterial species from one abscess (16.6%).

Arcanobacterium pyogenes along with *Escherichia coli* was isolated from one abscess (16.6%).

- *Fusobacterium necrophorum*

Fusobacterium necrophorum was isolated in one case of abscess mixed with both *Arcanobacterium pyogenes* and *Escherichia coli* (16.6%).

- *Escherichia coli*

Escherichia coli was isolated from one case of abscess as a mixture with other bacteria, including *Arcanobacterium pyogenes* and *Streptococcus species* (16.6%).

Table 1. Frequency of bacteria isolated from liver abscess cultures of slaughter goats in Rasht slaughterhouse

Bacteria	Number of isolates	Pure	Mixed with other species	
Corynebacterium pseudotuberculosis	2	1	1	*Pseudomonas spp*
Arcanobacterium pyogenes	2	1	1	*Escherichia coli*
Fusiobacterium necrophorum	1	-	1	*Arcanobacterium pyogenes / Escherichia coli*
Escherichia coli	1	-	1	*Arcanobacterium pyogenes / Streptococcus spp*

Source: Authors' own elaboration

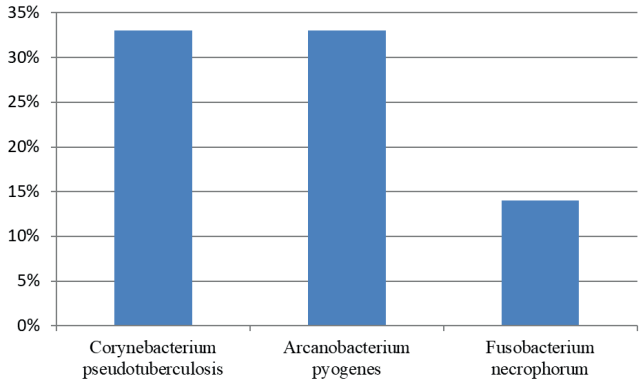

Diagram 2. Bacterial culture results. Percentage of bacterial isolates from abscesses
Source: Authors' own elaboration

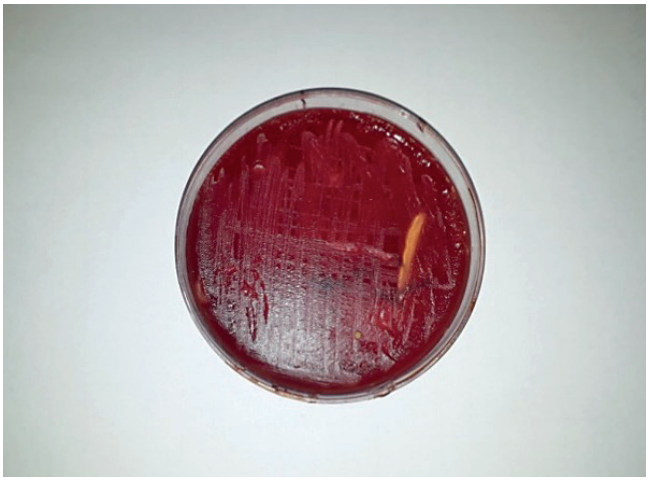

Single colonies

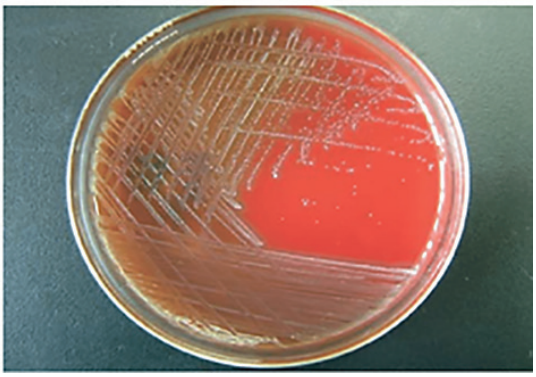

Fig. 2. Petri dish containing blood agar culture medium for *Arcanobacterium pyogenes* culture. Note the bacterial colony growth pattern
Source: Authors' own elaboration

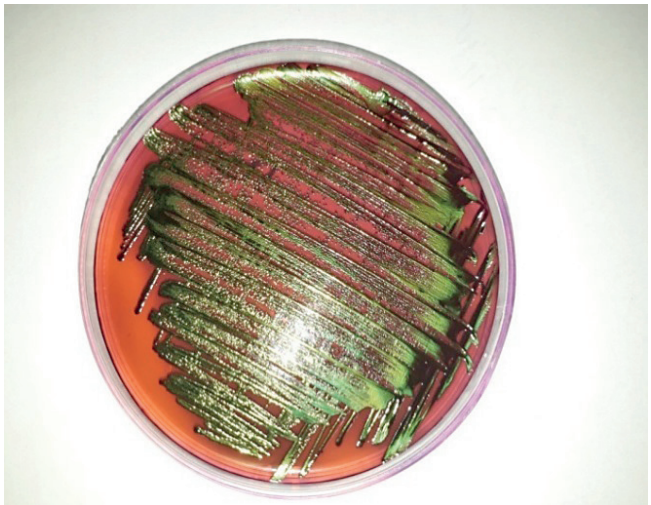

Single colonies

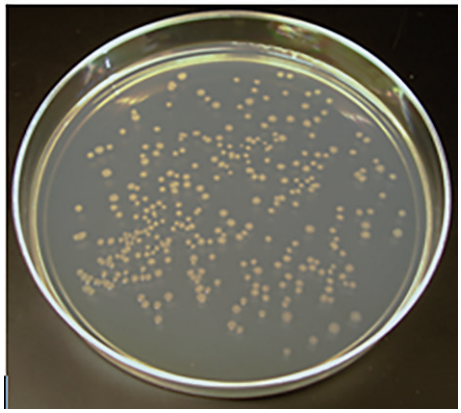

Fig. 3. Petri dish containing blood agar culture medium for the cultivation of *Escherichia coli* bacteria. Note the bacterial colony growth pattern
Source: Authors' own elaboration

Histopathological findings

According to histopathological studies, thick and thin capsules were observed around the abscesses. Abscesses contained purulent contents originating from necrotic tissues (condensate necrosis and in some cases caseous necrosis), and were surrounded by abundant infiltration of polymorphonuclear neutrophils and several mononuclear cells (macrophages). The purulent contents of these abscesses included green, white to yellow, and mucoadhesive purulent materials. In some cases, calcified centers were also observed in the central areas of these abscesses (Figures 6 to 8).

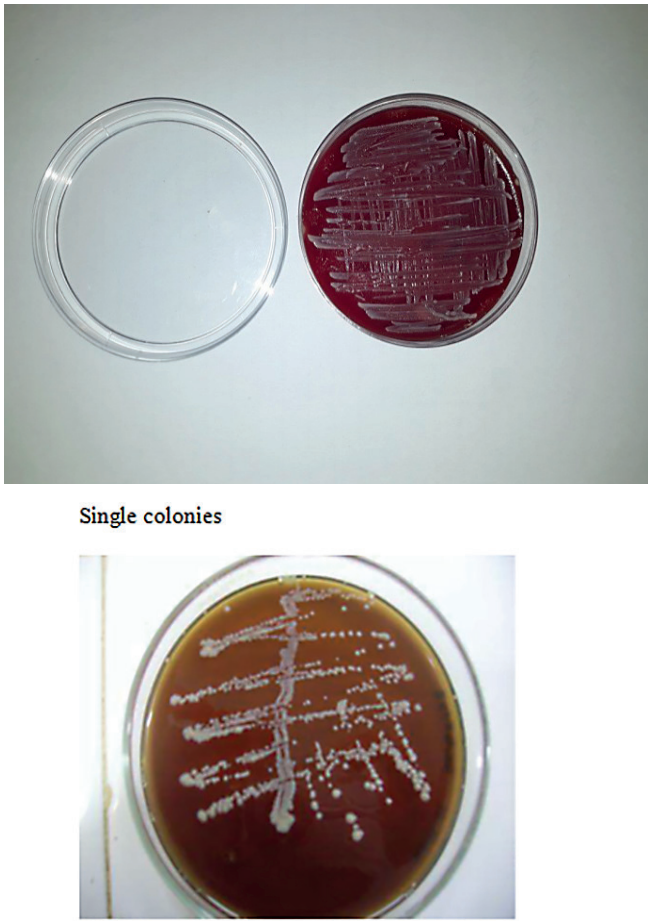

Fig. 4. Petri dish containing blood agar culture medium for the cultivation of *Corynebacterium pseudotuberculosis.* Note the bacterial colony pattern
Source: Authors' own elaboration

Fig. 5. Petri dish containing agar culture medium for streptococcal culture. Note the bacterial colony pattern
Source: Authors' own elaboration

Discussion and Conclusion

The occurrence and relative frequency of liver abscesses in cows is high. Nagaraja et al. (1999), Nagaraja and Lechtenberg (2007), and Sonawane et al. (2016) reported the numbers 12% to 32%, 78% and 6.6%, respectively.

In buffaloes, these figures are lower than the results obtained in the case of cows. The findings of the research of Jorgenson et al. (2007) and Tadepalli et al. (2009) regarding the occurrence and frequency of liver abscesses in buffalo, mentioned the numbers 0.9% and 0.99%, respectively. They attributed these results directly to the feeding pattern of livestock because buffaloes mainly use fodder and roughage materials.

In the case of sheep, there are also significant results. Araghi Soreh et al. (2010) in their studies on the occurrence and relative frequency of liver abscesses in slaughtered sheep reported a prevalence rate of 1.47%. This finding is much lower compared to the findings of Scanlan and Edward (1990) and Al-Qudah and Al-Majali (2002), who reported 3% and 16.4%, respectively. They attributed this decrease to nutritional differences or the presence of other underlying factors, such as parasitic liver infections like fascioliasis.

Santa Rosa et al. (1989) reported a frequency of 2.5% in their study of liver abscesses in slaughter goats in Bra-

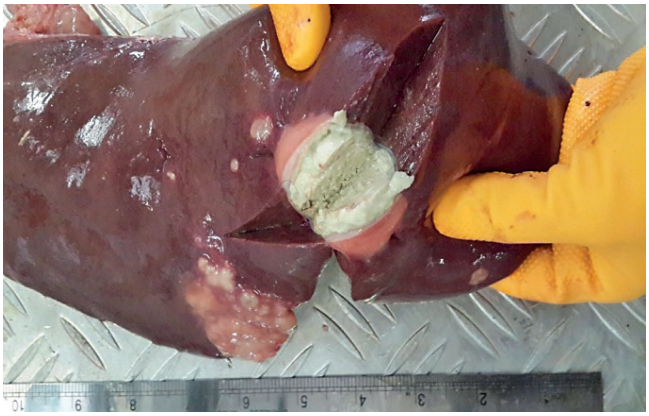

Fig. 6. The liver abscess is split open to identify its contents. Note the hard and caseous consistency of the contents and fibrosis capsules of liver abscess
Source: Authors' own elaboration

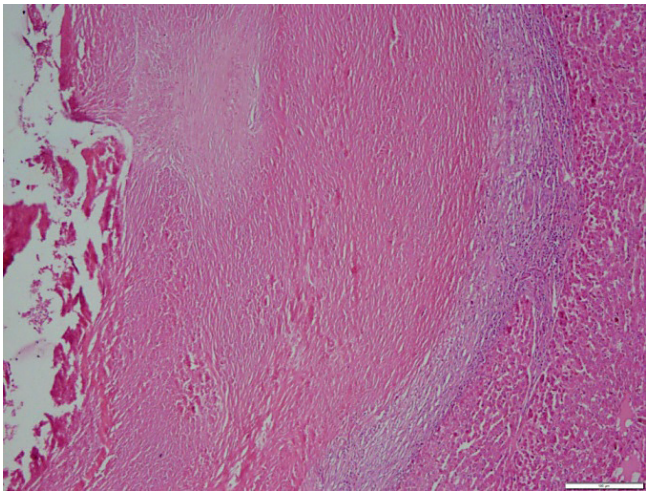

Fig. 7. Photomicrograph of liver abscess, magnification 400, H&E staining
Source: Authors' own elaboration

zil. Araghi Soreh and Firouzi (2012) in their studies in the same field reported the number 0.5% for the slaughter goats in Urmia city. This value is not only one fifth of the findings of Santa Rosa et al. (1989), but also has the lowest figure compared to other ruminants in Iran.

According to the present results and comparing them with the results of the previous findings, it is concluded that the frequency of liver abscesses in the present study is very low. Valkova et al. (2023) consistent with the results of the present experiment attributed the occurrence of such promising results to the feeding pattern and the low percentage of the underlying diseases of liver abscesses, such as toxic ru-

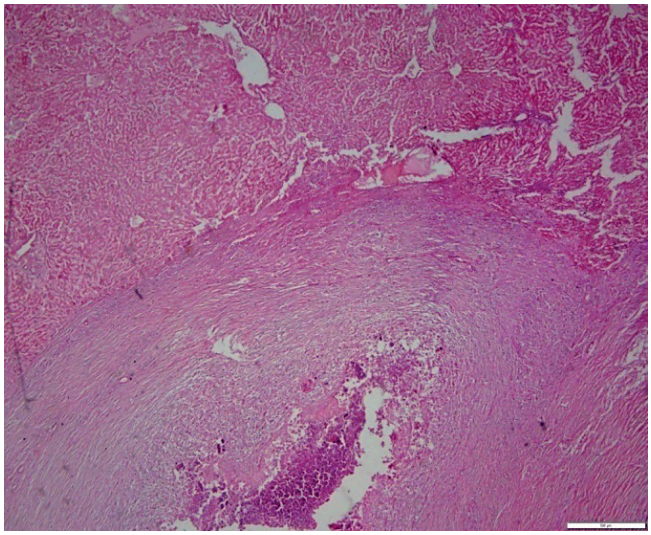

Fig. 8. Photomicrograph of liver abscess, magnification 100, H&E staining
Source: Authors' own elaboration

menitis and damage to the rumen mucosa with rumen lactic acidosis due to consumption of high-energy rations.

Regarding the etiology of liver abscesses in goats, Santa Rosa et al. (1989) and Araghi Soreh and Firouzi (2012) reported *Corynebacterium pseudotuberculosis* as the most frequent bacterial isolate from liver abscesses in slaughter goats from Brazil and Iran, respectively. In terms of the frequency and importance of *Corynebacterium pseudotuberculosis* in goat liver abscesses, the findings of the present research are consistent with the findings of the aforementioned researchers. Meanwhile, Benavides et al. (2015) reported *Fusobacterium necrophorum* as the most common bacterial isolate in their studies, on the type and frequency of etiological factors of liver abscesses in slaughtered sheep.

The findings of other researchers about the etiology of liver abscesses in cattle determined that *Fusobacterium necrophorum*, which forms part of the normal flora of the rumen and intestine of cattle, is the most frequent organism isolated from liver abscesses in cattle (Amachawadi and Nagaraja, 2016).

With a general comparison of existing findings, it is concluded that although *Fusobacterium necrophorum* is the most important bacterial isolate from liver abscesses of cattle, buffalo, and sheep, *Corynebacterium pseudotuberculosis* is an important etiological agent and bacterial isolate in goat liver abscesses. These results suggest that in goats, the ruminal route is not the only route of bacterial transfer from the rumen to the liver, while the ruminal route is the usual route for the transfer of bacteria from the rumen to the liver in oth-

er ruminants (Nincakova et al., 2022; Tadepalli et al., 2009).

Corynebacterium pseudotuberculosis is the cause of caseous lymphadenitis, which mainly exerts its pathogenicity by causing abscesses in superficial lymph nodes. However, when the disease becomes generalized, abscesses can be found in other visceral organs such as lungs, spleen, kidneys, and especially liver (Matthews, 2009; Umer et al., 2020).

In previous studies, *Corynebacterium pseudotuberculosis* was reported as the second most freqeunt bacterial isolate from liver abscesses of slaughtered sheep (Abebe and Sisay, 2015; Singh et al., 2018). However, in other studies, *Arcanobacter pyogenes* was reported as the second most frequent bacterial agent isolated from sheep liver abscesses (Levy et al., 2009; Shedon, 1995). Therefore, the existing reports about the presence of *Corynebacterium pseudotuberculosis* in liver abscesses of sheep and goats reveal the importance of caseous lymphadenitis in these two livestock species.

In the present study, *Fusobacterium necrophorum* was observed with a low frequency (10%) in liver abscesses. Similar to the results of the present experiment, Nagaraja and Chengappa (1998) and Araghi Soreh and Firouzi (2012) reported regarding the identification of the etiological factors of liver abscesses in cattle and goats, respectively, about the presence of this bacterium (14% and 10%) in the liver abscesses of cattle and goats.

Arcanobacterium pyogenes at the level of 20% was another isolate identified in the present study, which has been proven in previous studies to be among rumen bacterial flora along with *Fusobacterium necrophorum*, which can enter the liver from the rumen (Tehrani et al., 2012).

Another isolate was *Escherichia coli*, which was isolated and identified as the third most frequent bacterial isolate from goat liver abscesses in the present study with a frequency of 20%. This bacterium can enter the liver through the larvae of intestinal parasites or bacteremia associated with diarrhea (Clifton et al., 2018).

Other isolates, with less frequency, include *Pseudomonas spp* and *Streptococcus spp*, which were isolated and identified at equal levels (10%) in the present study. Consistent with the results of the present experiment, Sá et al. (2013) and Shedon (1995) also reported these two isolates with a low frequency in sheep liver abscesses. These two isolates, which were observed along with other bacteria, probably entered the liver through the umbilical route or bacteremia originating from diarrhea (Ishiyama et al., 2017).

In histopathological studies, purulent focal areas were observed in the liver parenchyma, which was characterized by the presence of caseous necrosis centers, surrounded by pyogenic membrane, along with infiltration of polymorphic cells, and a small number of mononuclear and macrophage cells. These findings were consistent with the findings of Nikkhah et al. (2022) and Abdulrahman et al. (2020).

The results of this study showed that *Corynebacterium pseudotuberculosis*, the cause of caseous lymphadenitis, is an important bacterial agent in causing liver abscesses in goats, killed in slaughterhouses, due to its specific pathogenicity for causing abscesses. Therefore, by identifying the bacterial agent and the ways to eliminate them, it is possible to prevent the reduction of the animal's growth performance and prevent large economic losses in the animal husbandry industry.

Acknowledgments

The authors thank to all the teams, who worked on the experiments and provided results during this study.

Financial support

This research received no grant from any funding agency/sector.

Data availability statement

The data supporting this study's findings are available from the corresponding author upon reasonable request.

Conflict of interest

The authors declare that they have no conflict of interest.

Author contribution

Afshin Zahedi, Mohammadreza Poorghasemi, Masoud Shirali did formal analysis, investigation, and methodology. Forogh Mohammadi and Maryam Karimi-Dehkordi did supervision, writing – review and editing.

References

Abdulrahman, R. F., Abdullah, M. A., Kareem, K. H., Najeeb, Z. D. & Hameed, H. M. (2020). Histopathological and molecular studies on caseous lymphadenitis in sheep and goats in duhok city, Iraq. *Explor. Anim. Med. Res.*, *10*, 134 – 140.

Abebe, D. & Sisay, T. T. (2015). Determination of Corynebacterium pseudotuberculosis prevalence and antimicrobial susceptibility pattern of isolates from lymph nodes of sheep and goats at an organic export abattoir, Modjo, Ethiopia. *Lett. Appl. Microbiol., 61*, 469 – 476.

Amachawadi, R. G. & Nagaraja, T. G. (2016). Liver abscesses in cattle: A review of incidence in Holsteins and of bacteriology and vaccine approaches to control in feedlot cattle. *J. Anim. Sci., 94*(4), 1620 – 1632.

Al-Qudah, K. & Al-Majali, A. (2002). Bacteriologic studies of liver abscesses of Awassi sheep in Jordan. *Small Rumin. Res., 47*(3), 249 – 253.

Araghi Soreh, A., Hasanpour, A. & Salimpour, A. (2010). Slaughterhouse and bacteriological study of liver abscesses in slaugh-

tered sheep, Urmia slaughterhouse. *J. Vet. Clin. Pathol., 16*(4), 21 – 23.

Araghi Soreh, A. & Firouzi, M. (2012). Bacteriological study of liver abscesses in goats slaughtered in Urmia slaughterhouse. *J. Vet. Clin. Pathol., 5*(1), 12 – 14.

Bancroft, J. D. & Stevens, A. (1982). Theory and Practice of histological technique. 2nd ed. London Churchil Livingston, 20 – 61.

Benavides, J., González, L., Dagleish, M. & Perez, V. (2015). Diagnostic pathology in microbial diseases of sheep or goats. *Vet. Microbiol., 181*, 15 – 26.

Clifton, R., Green, L. E. & Purdy, K. J. (2018). Development and validation of a multiple locus variable number tandem repeat analysis (MLVA) scheme for *Fusobacterium necrophorum*. *Vet. Microbiol., 213*, 108 – 113.

Domenis, L., Spedicato, R., Pepe, E., Orusa, R. & Robetto, S. (2018). Caseous lymphadenitis caused by *Corynebacterium pseudotuberculosis* in alpine chamois (*Rupicapra r. rupicapra*): a review of 98 cases. *J. Compar. Pathol., 161*, 11 – 19.

Gascoigne, E., Ogden, N., Lovatt, F. & Davies, P. (2020). Update on caseous lymphadenitis in sheep. In: *Practice, 42*, 105 – 114.

Ishiyama, D., Mizomoto, T., Ueda, C., Takagi, N., Shimizu, N., Matsuura, Y., Makuuchi, Y., Watanabe, A., Shinozuka, Y. & Kawai, K. (2017). Factors affecting the incidence and outcome of *Trueperella pyogenes mastitis in cows*. *J. Vet. Med. Sci., 79*, 626 – 631.

Jorgenson, K. F., Sehested, J. & Vestergaard, M. (2007). Effect of starch level and straw intake on animal performance, rumen wall characteristic and liver abscesses in intensively fed Friesian bulls. *Anim., 1*(6), 797 – 803.

Levy, C. E., Pedro, R. J., Von Nowakonski, A., Holanda, L. M., Brocchi, M. & Carvalho Ramos, M. (2009). Arcanobacteriumpyogenes sepsis in farmer. *Brazil Emerg. Infect. Dise., 15*, 1131 – 1132.

Mahmood, Z., Jesse, F., Saharee, A., Jasni, S., Yusoff, R. & Wahid, H.(2015). Clinio-pathological changes in goats challenged with Corynebacterium Peudotuberculosis and its exotoxin (PLD). *Am. J. Anim. Vet. Sci., 10*, 112 – 132.

Matthews, J. (2009). Diseases of the Goat.3rd Edition. *Wiley-Blackwell, Oxford*, 144.

Mathewos, M. & Fesseha, H. (2022). Cytopathological and bacteriological studies on caseous lymphadenitis in cattle slaughtered at Bishoftu municipal abattoir, Ethiopia. *Vet. Med. Sci., 8,* 1211 – 1218.

Morales, N., Aldridge, D., Bahamonde, A., Cerda, J., Araya, C., Muñoz, R., Esther Saldías, M., Lecocq, C., Fresno, M., Abalos, P. & Retamal, P. (2017). *Corynebacterium pseudotuberculosis* infection in Patagonian Huemul (*Hippocamelus bisulcus*). *J. Wildlife. Dis., 53*, 621 – 624.

Nagaraja, T. G. & Chengappa, M. M. (1998). Liver abscesses in feedlot cattle: a review. *J. Anim. Sci., 76*, 287 – 298.

Nagaraja, T. G., Beharka, A. B., Chengappa, M. M., Carroll, L. H., Raun, A. P., Laudert, S. B. & Parrott, J. C. (1999). Bacterial flora of liver abscesses in feedlot cattle fed tylosin or no tylosin. *J. Anim. Sci., 77*(4), 973 – 981.

Nagaraja, T. G. & Lechtenberg, K. F. (2007). Liver abscesses in feedlot cattle. *Vet. Clin. North. Am. Food. Anim. Pract., 23*(2), 351 – 369.

Nikkhah, A., Khabbazan, M., Rezagholivand, A., Rajaei, A., Mokhtarzadeh, S., Mousapour, H. & Moradi, M. (2022). Crossbreeding Balouchi sheep with Romanov: A profitable strategy to improve litter size, lamb growth, and carcass characteristics. *Iran. J. Appl. Anim. Sci.*, *12*(4), 733 – 737.

Nincakova, S., Vecerek, V., Valkova, L., Voslarova, E., Kaluža, M. & Zavřelová, V. (2022). Health status of slaughtered animals as indicated by post-mortem inspection at slaughterhouses. *Acta Vet., 91*, 99 – 106.

Sá, M. C. A., Veschi, J. L. A., Santos, G. B., Amanso, E. S., Oliveira, S. A. S., Mota, R. A., Veneroni-Gouveia, G. & Costa, M. M. (2013). Activity of disinfectants and biofilm production of Corynebacterium pseudotuberculosis. *Pesq. Vet. Brasileira, 33*(11), 1319 – 1324.

Santa Rosa, J., Johnson, E. H., Alves, F. S. F. & Fantos, L.(1989). A retrospective study of hepatic abscesses in goats: pathological and microbiological findings. *British Vet. J., 145*(1), 73 – 76.

Scanlan, C. M. & Edward, J. F. (1990). Bacteriologic and pathologic studies of hepatic lesion in sheep. Am. J. Vet. Res., *51*, 365 – 366.

Shedon, I. M. (1995). Hepatic abscess due to fascioliasis. *Vet. Rec., 4*, 304 – 312.

Singh, R., Singh, R., Kamdi, B., Kamari, S., Singh, S., Singh, S. V., Chauhan, P. & Kumar, S. (2018). Pathology of caseous lymphadenitis in slaughtered goats associated infection with corynebacterium pseudotuberculosis. *J. Anim. Res., 8,* 497 – 500.

Sonawane, G., Kumar, J. & Sisodia, S. (2016). Etio-pathological study of multiple hepatic abscesses in a goat. *Indian J. Vet. Pathol., 40*, 257 – 260.

Tadepalli, S., Narayanan, S. K., Stewart, G. C., Chengappa, M. M. & Nagaraja, T. G. (2009). Fusobacterium necrophorum: a ruminal bacterium that invades liver to cause abscesses in cattle. *Anaerobe, 15*, 36 – 43.

Tehrani, A., Javanbakht, J., Hassan, M. A., Zamani, M., Rajabian, M., Akbari, H. & Shafei, R. (2012). Histopathological and bacteriological study on hepatic abscesses of Herrik sheep. *Med. Microbiol. Diagn., 1*, 115 – 119.

Torky, H. A., Saad, H. M., Khaliel, S. A., Kassih, A. T., Sabatier, J. M., El-Saber Batiha, G., Hetta, H. F., Elghazaly, E. M. & De Waard, M. (2023). Isolation and molecular characterization of Corynebacterium pseudotuberculosis: Association with proinflammatory cytokines in caseous lymphadenitis pyogranulomas. *Animals*, *13*, 296 – 305.

Umer, M., Jesse, F. F. A., Saleh, W. M. M., Teik Chung, E. L., Haron, A. W., Saharee, A. Z., Azmi Mohd Lila, M., Bin Ariff, A., Mohammad, K. & Sharif, A. (2020). Histopathological changes of reproductive organs of goats immunized with Corynebacterium pseudotuberculosis killed vaccine. *Microb. Pathog., 149*, 1 – 9.

Valkova, L., Voslarova, E., Nincakova, S., Passantino, A. & Vecerek, V. (2023). The incidence of liver damage found during postmortem examination at the slaughterhouse. *Animals*, *13*, 839 – 845.

Received: **August, 15, 2024**; *Approved*: **November, 07, 2024**; *Published*: **February, 2026**